

## CASE REPORT

### A 15-year-old boy who presented with cardiac arrest and right ventricular mass: Not all the intra-cardiac masses are neoplastic

Anjum Jalal<sup>1</sup>, Abdul Razzaq Mughal<sup>2</sup>, Irfan Rasheed<sup>1</sup>, Asif Rashid Alamgir<sup>3</sup>

<sup>1</sup> Department of Cardiac Surgery, Faisalabad Institute of Cardiology, Faisalabad, Pakistan

<sup>2</sup> Department of Pediatric Cardiology, Faisalabad Institute of Cardiology, Faisalabad, Pakistan

<sup>3</sup> Department of Anesthesia, Faisalabad Institute of Cardiology, Faisalabad, Pakistan

Received: 4-December-2017.

Accepted 18-December-2017

DOI: 10.13140/RG.2.2.15734.09287

Correspondence:

Prof. Anjum Jalal, Executive Director, Faisalabad Institute of Cardiology, Serena Road, Faisalabad, Pakistan. Email: anjumjalal1@hotmail.com | Tel: +923214891250 | Fax: +92419201518

#### ABSTRACT

A 15-year-old boy was brought to our tertiary care institute of cardiology in unconscious stay after initial resuscitation at a local hospital of a small town. The initial mode of presentation was ventricular fibrillation with a back ground of low grade fever. The detailed investigations revealed right ventricular mass with lymphadenopathy. We conducted a mediastinal lymph node biopsy and treated him with anti-tuberculosis therapy which resolved the mass completely.

KeyWords: Cardiac tumor, Tuberculoma, Tuberculous endocarditis, Sudden Cardiac Death, Ventricular Fibrillation, Tuberculosis

#### INTRODUCTION

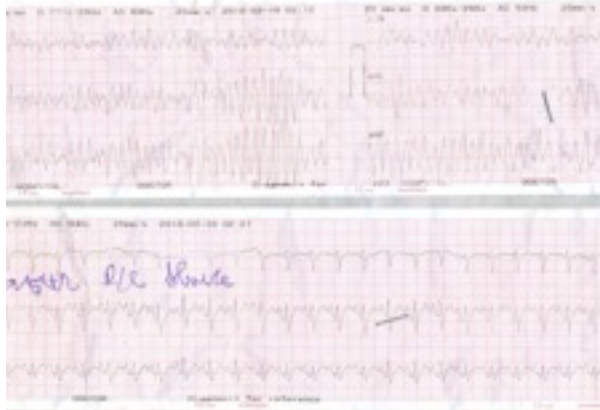The primary cardiac tumors are extremely rare entity and are found in 0.05% of necropsies [1]. Nearly three quarter of the tumors are benign. The common types of benign cardiac tumors are myxoma, lipoma, fibroelastoma, rhabdomyoma, angioma and hemangioma. The fibrosarcoma and rhabdomyosarcoma are common amongst the malignant primary cardiac tumors. By far the commonest type of cardiac tumor is myxoma.

The cardiac tumors are diagnosed either incidentally or the present indirectly with complications like embolism, valvular obstruction, arrhythmias or constitutional symptoms [2]. While most of the cardiac masses are neoplastic, the non neoplastic causes like organized thrombi and vegetations should also be kept in the list of differential diagnosis.

#### CASE REPORT

In March 2016, a 15-year-old boy suffered from low grade fever, right sided chest pain and dry cough for 15 days, which did not respond to treatment by local general practitioner. On 15th day of illness he suffered from sudden loss of consciousness and was brought to the local hospital of town. He underwent cardiopulmonary resuscitation during which ECG was done. The ECG showed ventricular fibrillation which was treated successfully with DC shock [Figure 1].

The patient was slow to regain consciousness and breathing was not satisfactory. He was ventilated and transferred to our tertiary care Cardiac Institute (Faisalabad Institute of Cardiology). At the time of admission the detailed interview of the parents failed to find anything remarkable about the present illness. There was



**Figure 1:** ECG at the time of presentation & after Direct Current (DC) cardioversion

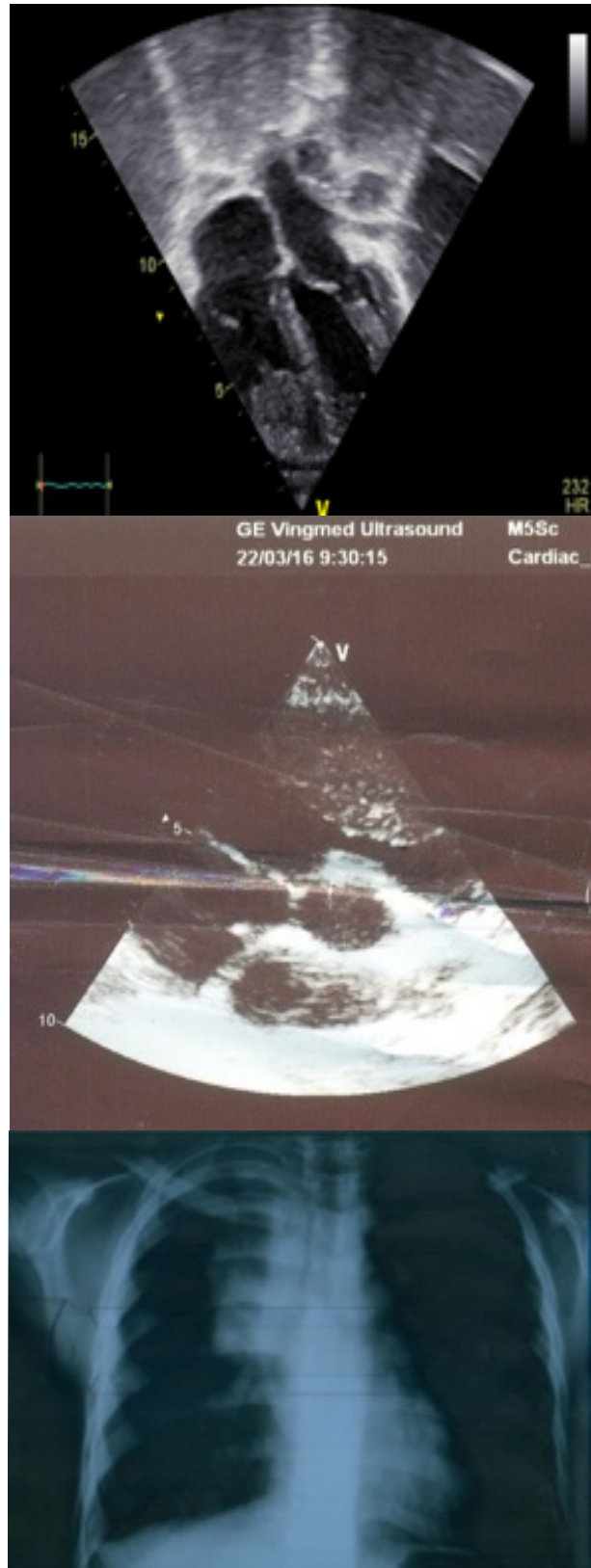
however, it was reported that one of the first degree cousins of the patients had sudden death of unknown cause at 11 years of age.

The detailed general physical examination of the patient was unremarkable. Auscultation of chest revealed a grade 2/6 ejection systolic murmur at left mid to upper sternal border. The patient was given routine ICU care where he had two more episodes of ventricular fibrillation and was given loading dose of Amiodarone and magnesium. This was followed by maintenance dose of amiodarone. These measures achieved stable normal sinus rhythm with QT interval of 0.28 sec and corrected QT interval of 0.43 sec (Fig 1).

The patient slowly recovered his normal conscious level within 24 hours and was transferred to cardiology ward within 72 hours. The detailed investigations were done. All the biochemical test including serum electrolytes, renal profile, liver function tests and thyroid function tests were normal. Hematological profile was also within normal range except raised ESR (38 mm) and slight neutrophilia (72%).

The heart rhythm was further investigated by 24-hours Holter monitoring which recorded sinus rhythm with slightly short PR interval. The maximum rate was 94 while the minimum rate noted during sleep was 43. However, there were 202 events of supraventricular ectopic, six couplets and one short run of supraventricular tachycardia. It also recorded 152 single ventricular ectopics and 37 couplets. There were no episodes of ventricular tachycardia or fibrillations.

The patient underwent echocardiography which showed a circumscribed, non mobile mass



**Figure 3:** Echo & X-Ray at the time of presentation

in the right ventricular cavity extending into the right ventricular outflow tract.

The chest X-ray was done which showed an radio-opaque shadow in right upper zone abutting superior vena cava. The trachea was central with normal bifurcation. The lung markings and cardiac shadows were within normal limits. There was no pleural effusion. The abdominal ultrasound showed enlarged lymph nodes of variable sizes along celiac axis, aorta, and porta-hepatis.

For a detailed work-up of neoplasia CT scan of abdomen, chest and brain was done. It showed enlarged matted lymph nodes around abdominal aorta as well as in posterior and superior mediastinum. The CT brain was unremarkable.

In order to get a histological diagnosis, right anterior mediastinotomy was performed and multiple nodes were sampled. The specimens were sent for histology as well as culture sensitivity. The histological examination showed scattered granulomas composed of collections of epithelioid histiocytes with admixed lymphocytes and plasma cell. The granulomas contained multiple Langhan type giant cells. Associated caseous necrosis was also seen.

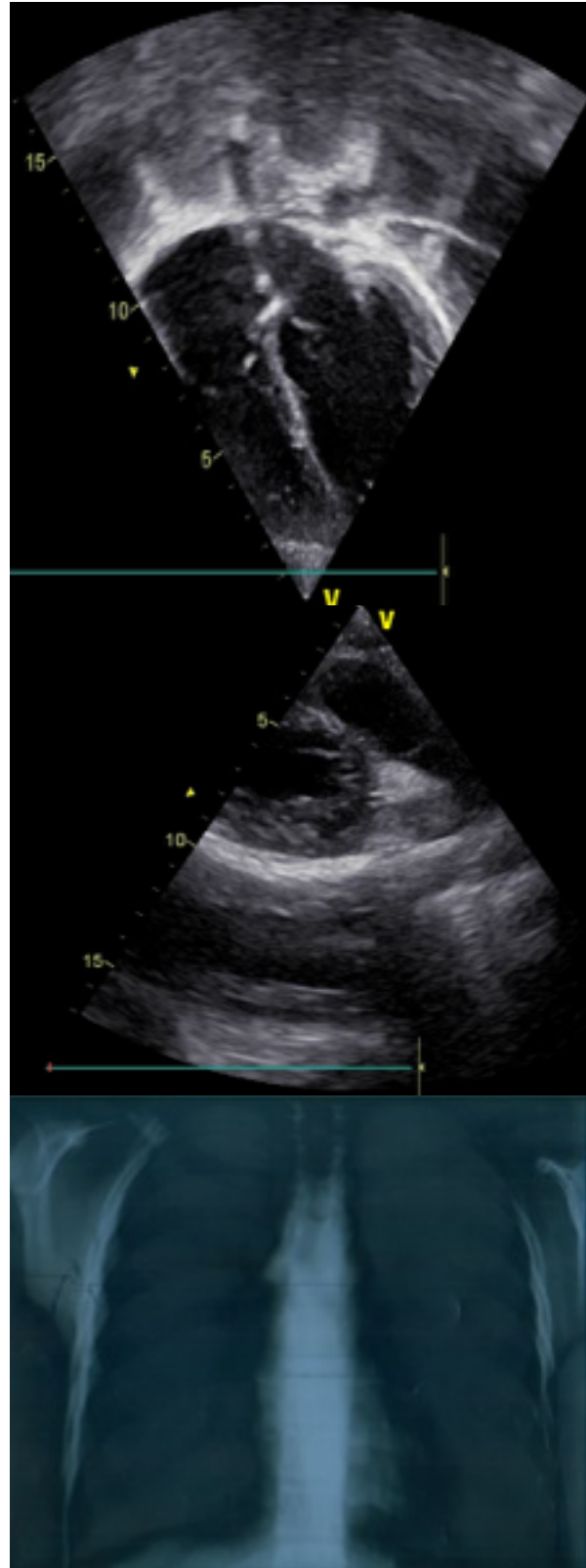
Based on the these findings, anti-tuberculous treatment was started in the first week of April 2016. The patient was put on a combination of four drugs namely Ethambutol Hydrochloride, Isoniazid, Pyrazinamide and Rifampicin. Prednisolone was also given initially at the dose of 1mg/kg/day for 4 wks and was then tapered off in next 2 wks. The Pyrazinamide and ethambutol were stopped after 3 months. The remaining two drugs i.e. Isoniazid and Rifampicin were continued for next 15 months.

A dramatic resolution of intra-cardiac mass as well as pulmonary shadow took place within six weeks of treatment [Fig]. The patient did have any arrhythmias since then. He is on long term follow-up and is enjoying good health.

## DISCUSSION

The tuberculous involvement of heart is claimed to be known from as early as 1664 [3]. However, as mentioned earlier it remains a rare phenomena and keeps surprising even the experienced clinicians as diagnostic conundrum.

This case is interesting due to several reasons. It highlights the importance of recognizing the fact that tuberculosis can effect any organ of body and spares no age group. It is therefore



**Figure 4:** Echo & X-Ray after six weeks of anti-TB treatment

extremely important to keep it in the differential diagnosis of all unusual masses in patients who come from communities with high prevalence. The cardiac involvement of tuberculosis has therefore been reported at very young ages of less than 18 months of age [4,5]. Different terminologies have been used to describe the cardiac involvement of tuberculosis e.g. cardiac tuberculosis, tuberculous endocarditis, and cardiac tuberculoma.

Cardiac tuberculomas are known to be extremely rare. Only few case reports exist in the literature. One autopsy study has reported 19 cases of intra-cardiac tuberculomas out of 13658 autopsies [6]. Since most of the cardiac tuberculomas cause serious arrhythmias and sudden cardiac death, this could be a reason for not getting them diagnosed in communities where rescue services are not efficient. The usual course of action after diagnosis of any cardiac mass is to do complete excision using cardiopulmonary bypass as the cardiac biopsy is technically difficult and may not provide adequate information [7]. Nevertheless, in our case the enlarged lymph nodes could provide histological diagnosis and avoid open heart surgery.

Another importance of this case report is to highlight the impact of improved healthcare services at grass root level. This child was initially treated at a Tehsil Headquarter hospital of a little town. These secondary care hospitals have remained neglected in our society and always lacked satisfactory healthcare services. The recent initiatives of the provincial government have resulted in provision of basic life saving equipment as well as availability of specialists. The patient underwent adequate resuscitation including DC cardioversion and was transferred safely to our specialized cardiac institute. A

prompt response at our institution followed by exhaustive diagnostic work-up not only saved the precious life of the patient but also avoided an undue sternotomy and open heart surgery.

## REFERENCES

- [1] Reynen K  
Frequency of primary tumors of the heart.  
AmJ Cardiol 1996;77:107.
- [2] Leonard M Shapiro  
Cardiac tumours: diagnosis and management  
Heart 2001 85: 218-222 doi: 10.1136/heart.85.2.218
- [3] Ariela Pomerance  
Tuberculoma of the interventricular septum  
Br Heart J 1963 25:412-414  
doi: 10.1136/hrt.25.3.412
- [4] Cantinotti M, De Gaudio M, de Martino M, Assanta N, Moschetti R, Veneruso G, Crocetti M, Murzi B, Chiappini E and Galli L  
Intracardiac left atrial tuberculoma in an eleven-month-old infant: case report.  
BMC Infectious Diseases 2011 11:359  
doi:10.1186/1471-2334-11-3
- [5] Vyas A, Rajeshwari K, Kurien S, Mehta V, Pandarikar N, Tyagi S.  
An unusual cardiac mass resolving with antitubercular treatment.  
Ann Pediatr Card 2014;7:204-6
- [6] Rose AG.  
Cardiac tuberculosis: a study of 19 patients.  
Arch Pathol Lab Med 1987;111:422-6.
- [7] Chang BC, Ha JW, Kim JT, Chung N, Cho S  
Intra-cardiac Tuberculoma  
Ann Thorac Surg 1999;67:226-8

Conflict of Interest: None declared  
Source of Funding: Nil  
Ethical Approval: From Ethical Review Committee of Faisalabad Institute of Cardiology

Cite this article as:  
*Jalal A, Mughal AR, Rasheed I, Alamgir AR.*  
15-year-old boy who presented with cardiac arrest and right ventricular mass: Not all the intra-cardiac masses are neoplastic.  
Pakistan Journal of Cardiovascular & Thoracic Surgery 2018;13(1);34-37  
**DOI: 10.13140/RG.2.2.15734.09287**